



Patient

NHS No

D.O.B.

Patient Ref

Reason

Varicose vein

Outcome

Incompetence

	Right		Left	
Deep Veins	Patency	Competency	Patency	Competency
Common Iliac Vein				
External Iliac Vein				
Internal Iliac Vein				
Common Femoral Vein			Widely Patent	Competent
Profunda Vein				
Superficial Femoral Vein				
Popliteal Vein			Widely Patent	Competent
Posterior Tibial Vein				
Anterior Tibial Vein				
Peroneal Vein				
Soleal Vein				
Gastrocnemius				
Superficial Veins				
Saphenofemoral Junction			Widely Patent	Incompetent
L Saphenous Vein Above			Widely Patent	Competent
L Saphenous Vein Below			Widely Patent	Competent
Vein of Giacomini			Widely Patent	Competent
Saphenopopiteal Junction			Not Identified	
S Saphenous Vein			Widely Patent	Competent
Evidence of D.V.T.				
Above the knee			No	
Popliteal			No	
Below the knee				

**Notes****LEFT LOWER LIMB VENOUS DUPLEX ASSESSMENT**

Iliac veins not viewed. Flow in the common femoral vein is phasic with respiration and a normal response on Valsalva manoeuvre, suggesting proximal vein patency. Common femoral and popliteal veins are widely patent and competent with no evidence of DVT.

Sapheno-femoral junction (SFJ) is incompetent. Long saphenous vein (LSV) is competent throughout its length.

An incompetent anterior thigh vein (ATV) is incompetent and linear down to distal thigh, with a slight kink in the prox-mid thigh. Incompetent branches leave the ATV in the distal thigh, forming the visible varicosities of the antero-medial thigh, the knee and lateral calf.

Transverse AP dimensions of ATV: prox-mid thigh 0.69cm.

Assessed by

Lukasz Koprowski

Checked by



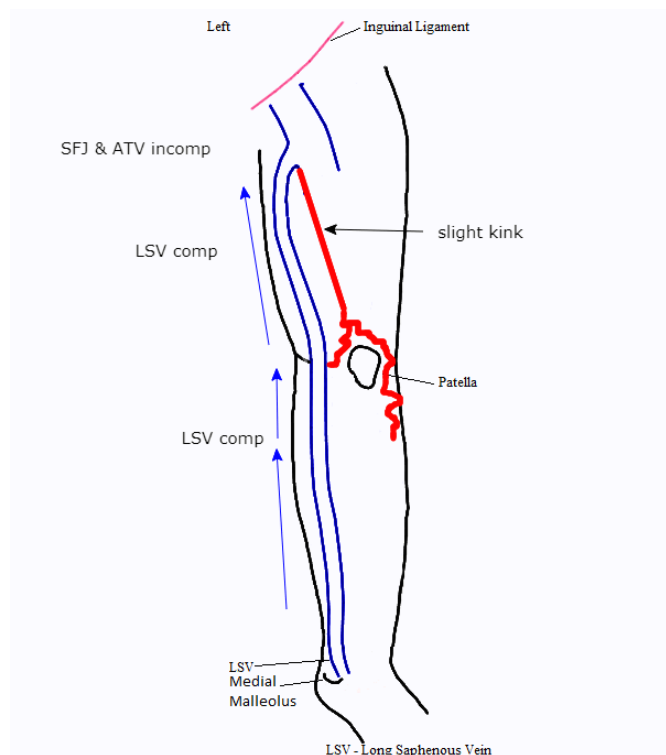
Patient

NHS No

D.O.B.

Patient Ref

Sapheno-popliteal junction (SPJ) was not identified. Short saphenous vein (SSV) is competent and is continuous with a competent vein of Giacomini.



Assessed by

Lukasz Koprowski

Checked by